

# Linear Porokeratosis With Underlying Bony Abnormalities

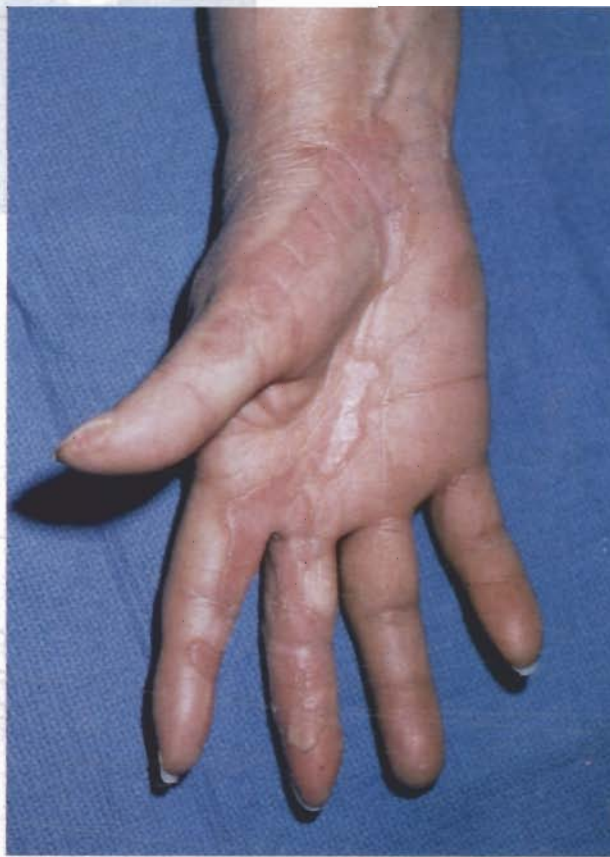Stephanie S. Tseng, MD; Eyal K. Levit, MD; Isabella Ilarda, MD; Maria C. Garzon, MD; Marc E. Grossman, MD

*A 58-year-old woman with linear porokeratosis involving the right hand and arm had distal digital narrowing and nail dystrophy with radiographic changes. Whereas isolated cases of bone resorption and flexion deformities with porokeratosis of Mibelli are known to occur, to our knowledge, bony abnormalities in association with linear porokeratosis have not been reported.*

Porokeratosis is a disorder of keratinization first described by Mibelli<sup>1</sup> as one or more slowly progressing hyperkeratotic plaques with prominent peripheral ridging and central atrophy. Five variants are recognized: porokeratosis of Mibelli; disseminated superficial actinic porokeratosis; porokeratosis palmaris, plantaris et disseminata (PPPD); punctate porokeratosis; and linear porokeratosis.<sup>1</sup> These may represent different phenotypic expressions of a common genetic defect—the peripheral expansion of a mutant clone of epidermal cells.<sup>2</sup> Porokeratosis of Mibelli, disseminated superficial actinic porokeratosis, and PPPD have autosomal dominant inheritance.

## Case Report

A 58-year-old woman presented with a 20-year history of hyperpigmentation and erythematous fissuring of her right hand. Examination revealed linear erythematous plaques with central atrophy and rolled borders on the right palm extending to the palmar and lateral surfaces of the thumb and second and third fingers. The second and third fingers also demonstrated distal narrowing with nail dystrophy and limited extension (Figures 1 and 2). Linear hyperpigmented patches were seen on the extensor surface of her right forearm and upper arm.

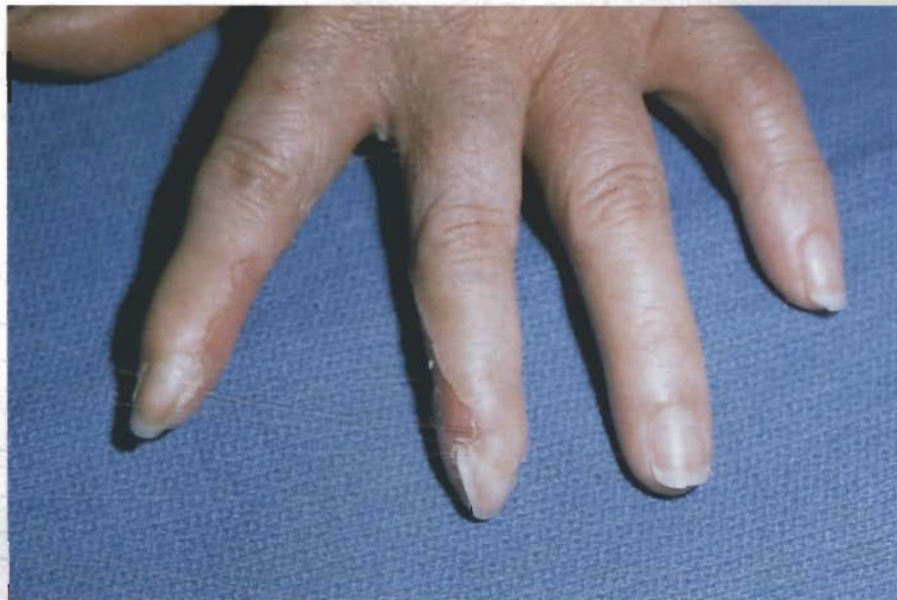

**Figure 1.** Linear erythematous plaques with central atrophy and raised borders.

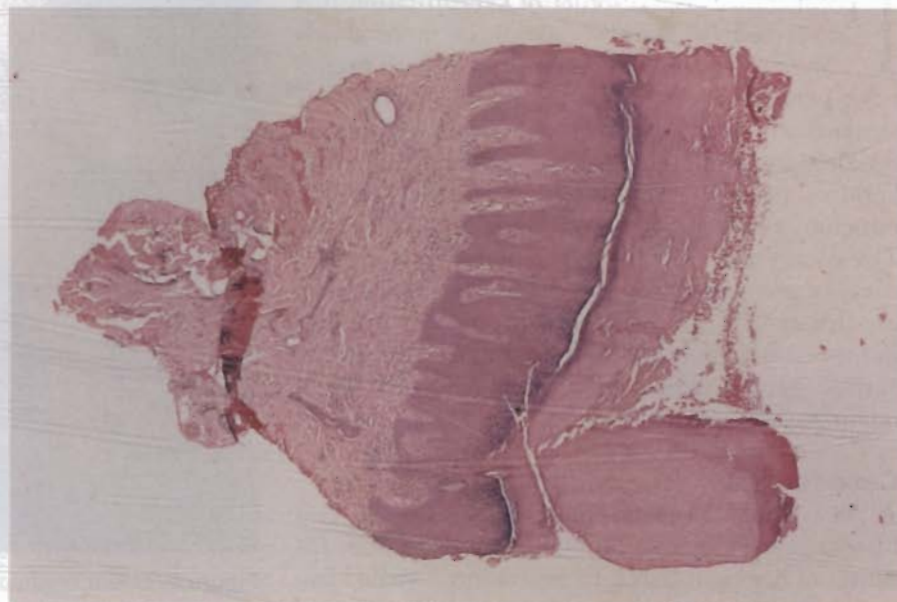
Skin biopsy results showed a narrow column of parakeratotic cells with underlying dermal infiltrate (Figure 3). Radiographic examination of the hands demonstrated tapering of the soft tissues of the right second and third fingers with erosion of the tufts (Figure 4). Laboratory data results indicated an erythrocyte sedimentation rate of 35, a negative antinuclear antibody, and negative anti-Scl-70 antibodies, ribonucleoproteins, Smith, and Ro/SSA and La/SSB antigens.

Partially effective treatments included twice-daily 5% 5-fluorouracil solution (under occlusion

Drs. Tseng, Levit, Garzon, and Grossman are from the Department of Dermatology, College of Physicians and Surgeons, Columbia University, New York. Dr. Ilarda is in private practice in Belmore, Long Island, and Brooklyn, New York. Reprints: Marc E. Grossman, MD, Columbia University, Department of Dermatology, 161 Ft Washington Ave, AP-7, New York, NY 10032.



**Figure 2.** Distal narrowing and nail dystrophy with overlying skin lesions.



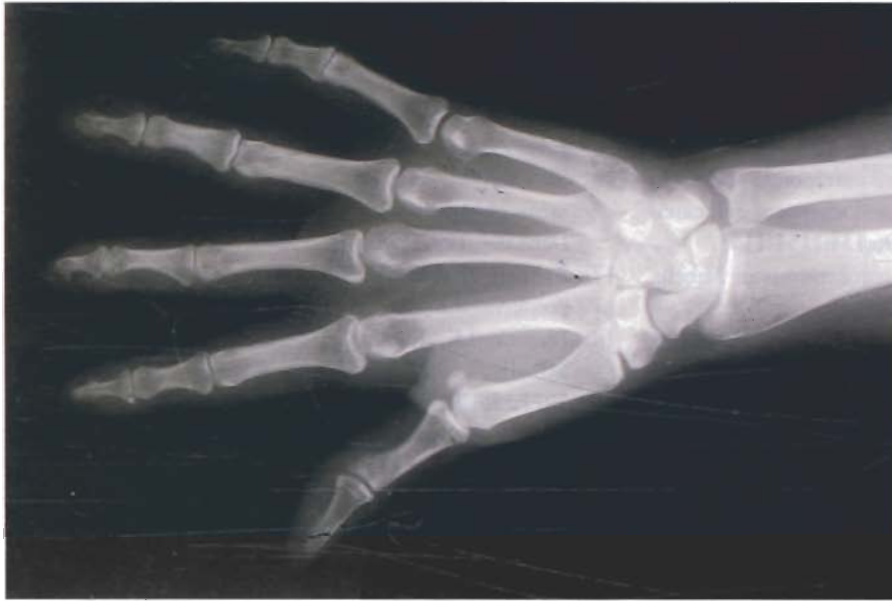**Figure 3.** Characteristic narrow column of parakeratotic cells (cornoid lamellae) (H&E, original magnification X4).

at night) with betamethasone valerate ointment, tretinoin solution 0.5%, intralesional triamcinolone 5 mg/mL, flurandrenolide tape, and combination tretinoin cream 0.1% and 5% 5-fluorouracil solution. The patient declined treatment with isotretinoin, etretinate, or dermabrasion. Daily treatments with tazarotene 0.5% gel, clobetasol propionate ointment, and ammonium lactate 12% lotion twice resulted in moderate plaque thinning and no fissure recurrence. Follow-up hand films showed no progression of bony changes.

#### Comment

Linear porokeratosis usually presents at birth or in childhood<sup>3,4</sup> (late onset in adults has been infrequently reported<sup>5</sup>), with sporadic occurrence. Papules or plaques with threadlike rims are distributed in a linear fashion following Blaschko lines. Ulcerations within lesions are rarely seen.<sup>3</sup>

Histopathology results of all variants of porokeratosis show the characteristic cornoid lamella, a tightly packed column of parakeratotic cells extending through the stratum corneum, overlying dyskeratotic



**Figure 4.** Tapering of soft tissues of right second and third fingers with tuft erosion.

cells, and vacuolated keratinocytes. Absent granular layer and central areas of liquefaction degeneration with colloid body formation are seen, in addition to upper dermal lymphocytic infiltrate.<sup>6</sup>

Porokeratotic lesions tend to increase in size and number over time. Development of intralesional squamous cell carcinoma, basal cell carcinoma, or Bowen's disease is well reported in the literature. The highest risk of malignant degeneration is in large, long-standing, or linear lesions.<sup>7</sup> It has been suggested that allelic loss in linear porokeratosis may explain the higher susceptibility to malignancy.<sup>8</sup> Overexpression of the tumor suppressor gene p53 has been shown in linear porokeratosis, as well as in its variants.<sup>9</sup>

Treatment of porokeratosis with topical agents such as keratolytics, 5-fluorouracil, corticosteroids, retinoids, and calcipotriol has had variable success.<sup>10,11</sup> Oral retinoid therapy has led to improvement (with relapse on discontinuation) and worsening of disease.<sup>12,13</sup> Surgical modalities such as curettage, excision, cryotherapy, and electrodesiccation have been utilized with recurrence after superficial procedures.<sup>10</sup> Successful use of carbon dioxide laser<sup>14</sup> and dermabrasion<sup>15,16</sup> without recurrence of the disease or scarring has been reported.

Facial involvement in porokeratosis is rare. A report was made by Rahbari et al<sup>17</sup> of 2 patients with facial porokeratosis of Mibelli with extensive destructive changes. Bhutani et al<sup>18</sup> described a patient with porokeratosis of Mibelli and PPPD who was noted to have bony resorption of the tips of the fingers and toes, flexion deformities of the

interphalangeal joints, and nail dystrophy. A similar loss of hand distal phalanges in addition to flexion deformities has been reported in a patient with extensive (approximately 100 lesions) bilateral symmetric porokeratosis of Mibelli.<sup>19</sup> Ramesh et al<sup>20</sup> reported pseudoainhum of the toes associated with porokeratosis of Mibelli. A patient with generalized distribution of porokeratosis following Blaschko lines (generalized linear porokeratosis) had syndactyly of the right second and third toes underlying skin lesions.<sup>13</sup> To our knowledge, bony abnormalities in association with localized linear porokeratosis, as seen in this patient, have not been previously reported.

## REFERENCES

1. Wolff-Schreiner EC. Porokeratosis. In: Fitzpatrick TB, Eisen AZ, Wolff K, et al, eds. *Dermatology in General Medicine*. 4th ed. New York, NY: McGraw-Hill Book Co; 1993:565-571.
2. Reed RJ, Leone P. Porokeratosis—a mutant clonal keratosis of the epidermis. *Arch Dermatol*. 1970;101:340-347.
3. Fisher CA, LeBoit PE, Frieden IJ. Linear porokeratosis presenting as erosions in the newborn period. *Pediatr Dermatol*. 1995;12:318-322.
4. Rahbari H, Cordero AA, Mehregan AH. Linear porokeratosis—a distinctive clinical variant of porokeratosis of Mibelli. *Arch Dermatol*. 1974;109:526-528.
5. Bogaert MA, Hogan DJ. Linear porokeratosis in a 74-year-old woman. *J Am Acad Dermatol*. 1991;25:338-340.
6. Johnson B, Honig P. Congenital diseases (genodermatoses). In: *Lever's Histopathology of the Skin*. 8th ed. Philadelphia, Pa: Raven Press; 1997:122-124.

7. Sasson M, Krain AD. Porokeratosis and cutaneous malignancy: a review. *Dermatol Surg.* 1996;22:339-342.
8. Happle R. Cancer proneness of linear porokeratosis may be explained by allelic loss. *Dermatology.* 1997;95:20-25.
9. Sasaki S, Urano Y, Nakagawa K, et al. Linear porokeratosis with multiple squamous cell carcinomas—study of p53 expression in porokeratosis and squamous cell carcinoma [letter]. *Br J Dermatol.* 1996;134:1151-1153.
10. Eyre WG, Carson WE. Linear porokeratosis of Mibelli. *Arch Derm.* 1972;105:426-429.
11. Hubler WR Jr, Michaelson JD, Knox JM. Linear porokeratosis. *Cutis.* 1974;14:61-64.
12. Knobler RM, Neumann RA. Exacerbation of porokeratosis during etretinate therapy. *Acta Derm Venereol.* 1990;70:319-322.
13. Goldman GD, Milstone LM. Generalized linear porokeratosis treated with etretinate. *Arch Dermatol.* 1995;131:496-497.
14. Barnett JH. Linear porokeratosis—treatment with the carbon dioxide laser. *J Am Acad Dermatol.* 1986;14:902-904.
15. Cohen PR, Held JL, Katz BE. Linear porokeratosis: successful treatment with diamond fraise dermabrasion. *J Am Acad Dermatol.* 1990;23:975-977.
16. Spencer JM, Katz BE. Successful treatment of porokeratosis of Mibelli with diamond fraise dermabrasion. *Arch Dermatol.* 1992;128:1187-1188.
17. Rahbari H, Fazel Z, Mehregan AH. Destructive facial porokeratosis. *J Am Acad Dermatol.* 1995;33:1049-1050.
18. Bhutani LK, Kanwar AJ, Singh OP. Porokeratosis of Mibelli with unusual features. *Dermatologica.* 1977;155:296-300.
19. Handa S, Dawn G, Kumar B. Mutilating lesions in porokeratosis of Mibelli. *Dermatology.* 1995;191:62-64.
20. Ramesh V, Misra RS, Mahaur BS. Pseudoainhum in porokeratosis of Mibelli. *Cutis.* 1992;49:129-130.